



# Osteochondral autologous transplantation for the treatment of full-thickness cartilage defects of the shoulder

## RESULTS AT NINE YEARS

J. Kircher,  
T. Patzer,  
P. Magosch,  
S. Lichtenberg,  
P. Habermeyer

From the ATOS  
Clinic, Heidelberg,  
Germany

**We describe the outcome at a mean follow-up of 8.75 years (7.6 to 9.8) of seven patients who had undergone osteochondral autologous transplantation for full-thickness cartilage defects of the shoulder between 1998 and 2000. These patients have been described previously at a mean of 32.6 months when eight were included. One patient has been lost to follow-up. The outcome was assessed by the Constant shoulder score and the Lysholm knee score to assess any donor-site morbidity. Standard radiographs and MR scores were obtained and compared with the pre-operative findings and the results from the previous review.**

**No patient required any further surgery on the shoulder. The mean Constant score improved significantly until the final follow-up ( $p = 0.018$ ). The Lysholm score remained excellent throughout. There was a significant progression of osteoarthritic changes from the initial surgery to the first and final follow-up but this did not appear to be related to the size of the defect, the number of cylinders required or the Constant score ( $p = 0.016$ ). MRI showed that all except one patient had a congruent joint surface at the defect with full bony integration of all osteochondral cylinders.**

**The results have remained satisfactory over a longer period with very good objective and subjective findings.**

The incidence of defects of the articular cartilage of the shoulder is estimated to be between 5% and 17% in athletes engaged in overhead sporting activity. Treatment remains a problem because of the limited capacity for repair.<sup>1,2</sup> The fibrocartilaginous repair stimulated by microfracture, drilling and abrasion chondroplasty lacks the resilience of hyaline cartilage.<sup>3-5</sup> Autologous chondrocyte implantation (ACI) as introduced by Brittberg et al<sup>6</sup> for the treatment of lesions at the knee has been developed with the addition of matrix or scaffold-associated techniques for use in clinical practice.<sup>7-9</sup> These methods often require a two-stage procedure and are expensive. It remains uncertain whether long-lasting hyaline-like cartilage can be generated.<sup>10-15</sup>

The use of structural allografts for the treatment of osteochondral defects at the knee and shoulder has been described, but not in controlled studies with sufficient numbers to draw conclusions about the outcome.<sup>16-19</sup> An alternative is the transplantation of autologous cartilage in conjunction with the underlying bone for small defects.<sup>20,21</sup> It has been shown that the primary stability of the osteochondral cylinders increases with the size and the use of bigger

cylinders of 8 mm to 12 mm.<sup>22,23</sup> The method has been described for almost all the large joints.<sup>24-33</sup> Although usually there are no problems with bony ingrowth, it should be noted that healing does not occur at the interface between the host cartilage and the transplanted cylinders.<sup>12,34-36</sup> We reported the use of this technique at the shoulder in a series of eight patients with good short-term results<sup>37</sup> and it is also reported in an isolated case report.<sup>38</sup> Our aim in this study was the re-evaluation of our series after a longer follow-up in regard to the clinical results and the development of osteoarthritis.

### Patients and Methods

Seven patients from the initial series were re-assessed at a mean follow-up of 8.75 years (7.6 to 9.8) by clinical examination and scoring, and standard radiography comprising true anteroposterior (AP) views in neutral, internal and external rotation and an axillary view, as well as by MRI. One patient had been lost to follow-up because of problems involving the donor site at the ipsilateral knee. This patient refused an invitation to re-attend, but reported his satisfaction with the shoulder and no current problem with his knee during a telephone interview.

■ J. Kircher, MD, Consultant Orthopaedic Surgeon  
■ T. Patzer, MD, Orthopaedic Registrar  
■ P. Magosch, MD, Orthopaedic Registrar  
■ S. Lichtenberg, MD, Consultant Orthopaedic Surgeon  
■ P. Habermeyer, MD, PhD, Professor Heidelberg Shoulder and Elbow Surgery, ATOS Clinic, Bismarckstrasse 9-15, D-69115, Heidelberg, Germany.

Correspondence should be sent to Dr J. Kircher; e-mail: kircher@atos.de

©2009 British Editorial Society of Bone and Joint Surgery  
doi:10.1302/0301-620X.91B4.21838 \$2.00

*J Bone Joint Surg [Br]*  
2009;91-B:499-503.  
Received 29 September 2008;  
Accepted 5 January 2009

**Table I.** Details of the patients, defects and procedures

Case	Age at initial surgery (yrs)	Gender	Yrs after index trauma/dislocation	Location of defect*	Size of defect (mm)	Number of osteochondral cylinders used	Hill-Sachs lesion <sup>52</sup>	Additional chondral lesion	Aetiology	Additional surgery
1	57.1	M	15	Central (h)	120	1	1	Dorsal glenoid rim lesion grade III	Traumatic anterior instability	Labral augmentation capsular shift
2	38.9	M	20	Posteromedial (h)	150	3	3	Anteroinferior glenoid lesion grade IV	Traumatic anterior instability	None
3	56.9	M	1	Central (h)	105	2	0	Glenoid cartilage lesion grade II	Post-traumatic	None
4	53.1	M	2	Postero-central (h)	105	2	0	Postero-inferior glenoid lesion grade I-II	Hyperlaxity	Labral augmentation, capsular shift
5	43.2	F	4	Anterocentral (g)	128	1	3	Postero-central humeral lesion grade IV	Traumatic anterior instability	Labral augmentation, capsular shift
6	44.4	M	0.5	Central (h)	144	1	0	Anterior glenoid lesion grade III	Hyperlaxity	None
7	23.4	M	3	Anterocentral (h)	250	3	0	Dorsal glenoid lesion grade I-II	Traumatic posterior instability	None

\* h, humeral; g, glenoid

**Table II.** Details of the presence of osteoarthritis according to Samilson and Prieto<sup>39</sup>

Case	Grade of osteoarthritis			Grade of glenohumeral distance (mm)		
	Pre-operatively	Follow-up 1	Follow-up 2	Pre-operatively	Follow-up 1	Follow-up 2
1	1	2	2	5.0	5.0	5.0
2	1	2	3	4.0	4.0	3.6
3	0	3	3	4.0	4.0	4.0
4	0	2	2	3.0	3.0	3.0
5	0	1	1	5.0	5.0	4.0
6	1	2	3	3.0	3.0	3.6
7	0	1	1	5.0	5.0	5.0

The presence of osteoarthritis was graded according to the method of Samilson and Prieto.<sup>39</sup> The joint space was measured as the minimum distance found on an AP view. The integrity of the osteochondral cylinder and congruity of the joint surface were assessed on standard MR scans. The Constant score<sup>40</sup> for the shoulder and the Lysholm score<sup>41</sup> of the knee from which the osteochondral graft had been harvested were calculated. Self-assessment of patients for the entire treatment was graded as very satisfied, or satisfied, not satisfied, or disappointed. The series and the interventions are described in Tables I and II.

**Statistical analysis.** This was performed using the Wilcoxon signed-rank test for non-parametric data with the level of significance set at a p-value  $\leq 0.05$ , for all seven patients at the final follow-up.

## Results

All the patients attending for review were subjectively very satisfied with the result and stated that they would have

undergone the procedure again. None of these patients had required any revision surgery for the shoulder or the operated knee.

The overall mean Constant score improved from 76.2 points (65.9 to 89.6) pre-operatively to 89.6 (83.4 to 95.4) at the first follow-up (32.6 months) and to 90.9 points (80 to 97) at the final follow-up. This increase in the score from operation to the first follow-up was statistically significant ( $p = 0.018$ ), but not from the first to the final follow-up ( $p = 0.612$ ). The pain component of the Constant score significantly improved from operation to the first follow-up in all patients ( $p = 0.018$ ). From the first to the final follow-up three patients showed no change in their pain level, three showed an increase in their pain score which did not reach statistical significance ( $p = 0.257$ ) and one showed an increase in the pain score of only one point from the first to the final follow-up. All patients significantly ( $p = 0.018$ ) increased the level of their activities of daily living from operation to the first follow-up with three patients

**Table III.** The Constant score (CS) with its components and the Lysholm score pre-operatively and at the first (FU-1) and the final follow-up (FU-2)

Case	Follow-up (yrs)	CS pre-operatively					CS first follow-up					CS final follow-up					Lysholm		
		Total	Pain	ADL*	ROM†(kg)	Strength	Total	Pain	ADL	ROM	Strength (kg)	Total	Pain	ADL	ROM	Strength (kg)	Pre-operatively	FU-1	FU-2
1	9.2	77.2	10	9	38	9.7	93.1	15	20	36	10.6	80	14	17	38	10.4	100.0	100.0	100.0
2	9.2	82.6	10	12	40	9.9	94.1	13	18	40	11.1	91.0	14	18	38	20	100.0	100.0	100.0
3	9.0	70.5	5	10	38	8.4	86.3	13	19	40	6.9	94.0	13	20	40	21	100.0	91.0	100.0
4	8.8	69.4	13	16	30	5	83.4	15	18	36	6.9	90.0	10	19	40	21	100.0	100.0	95.0
5	7.7	78.4	12	17	40	4.5	87.5	15	20	40	6	90.0	15	20	40	15	100.0	100.0	100.0
6	7.6	65.9	5	14	40	3.3	87.7	15	20	40	6.1	97.0	14	18	40	25	100.0	100.0	100.0
7	9.8	89.6	10	18	40	10.4	95.4	15	20	40	9.9	94.0	15	20	38	21	100.0	87.0	100.0

\* ADL, activities of daily living

† ROM, range of movement

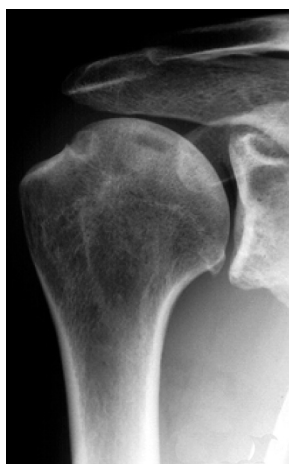

Fig. 1a

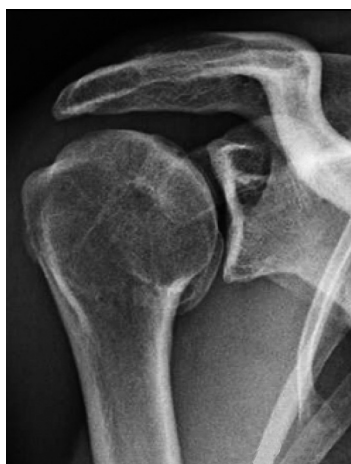

Fig. 1b

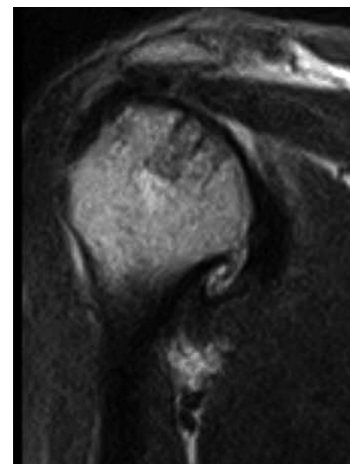


Fig. 1c

Anteroposterior radiographs a) showing little degenerative change (Samilson and Prieto, grade 1) in a 39-year-old man with a history of traumatic anterior instability which began 20 years earlier and b) after osteochondral autologous transplantation with three cylinders to cover a defect of 150 mm<sup>2</sup> at the posteromedial humerus showing an increase after 7.6 years and the presence of a large inferior osteophyte (Samilson-Prieto grade 3). c) MR scan showing full and flush integration of the osteochondral cylinders at the final follow-up.

maintaining this level, two showing a slight decrease, which was not statistically significant ( $p = 0.461$ ), and two showing an increase from the first to the final follow-up. The range of movement was good for all patients at every stage of assessment. All the patients, except one who had little change, significantly increased their strength from the first to the final follow-up ( $p = 0.028$ , Table III).

The Lysholm score was 100 points for all patients before operation, with a mean of 96.9 (87 to 100) at the first and of 99.3 (95 to 100) at the final follow-up. Four patients had no disturbance in their knee function through the whole course, two were returned to full knee function after the first follow-up and one showed a marginal decline from 100 to 95 points at the final follow-up (Table III).

An increase was found in the osteoarthritic grade according to Samilson and Prieto<sup>39</sup> from the pre-operative findings to the first and the final follow-up which was statistically significant at the first interval but not for the changes between the first ( $p = 0.014$ ) and final follow-up ( $p = 0.157$ ). All

patients showed an increase of at least one grade in the Samilson and Prieto classification from operation to the first follow-up. There did not appear to be any relationship between the size of defect or the number of osteochondral cylinders used for the repair and the development of osteoarthritis (Tables I and II, Fig. 1). Changes to the measured width of the glenohumeral joint space were much less pronounced than the increase in the Samilson and Prieto grade and did not appear to be directly related to it (Tables I and II). Neither the arthritic changes according to Samilson and Prieto grades nor decrease of glenohumeral joint space seemed to be reflected in the overall Constant score or its component parts (Tables I, II and III).

All except one patient presented a congruent joint surface on the final MR scan and all cylinders showed full integration with the surrounding bone. One patient whose MR scan indicated partial osteonecrosis of the bony part of the osteochondral cylinder at the first follow-up showed complete recovery at the final follow-up (Table IV).

**Table IV.** MRI findings at the first and final follow-up

Case	MRI first follow-up			MRI final follow-up		
	Integrity	Glenoid lesion	Joint surface congruency	Integrity	Glenoid lesion	Joint surface congruency
1	Intact	No	Yes	Intact	No	Yes
2	Intact	No	Yes	Intact	No	Yes
3	Intact	No	Yes	Intact	No	No
4	Avascular necrosis	No	Yes	Intact	No	Yes
5	Intact	Yes	Yes	Intact	No	Yes
6	Intact	No	Yes	Intact	No	Yes
7	Intact	No	Yes	Intact	No	Yes

## Discussion

Our findings have shown no deterioration over a longer period of follow-up, and no complications at the shoulder have emerged. Donor-site morbidity at the knee was not a problem except in one patient in the original series who required two additional operations which resulted in a good result, but he declined to participate in this further review. The development of arthritic changes at the operated shoulder was found in all patients, this was already detectable at the first follow-up at a mean of 32 months (8 to 47), and in two patients who showed further progression at the final follow-up. These radiological findings were not matched by any functional restriction, pain or loss of patient satisfaction. This was similar to the findings of Knutsen et al<sup>13,14</sup> in a randomised trial comparing ACI and microfracture at the knee and those of Hovelius et al<sup>42</sup> in a follow-up study at 25 years of primary anterior dislocation of the shoulder.

Our study could not determine whether the arthritic changes at the shoulder were due to the osteochondral transplantation or reflected the natural course of the underlying disease, the initial trauma or instability. Three patients in our series had a Hill-Sachs lesion at the time of the initial operation and all had additional chondral lesions at the humerus, the glenoid or both. Progressive degeneration of the shoulder has been described in post-traumatic instability managed conservatively and operatively.<sup>39,42-50</sup>

Buscayret et al<sup>51</sup> found an association of the development of glenohumeral arthritis with the presence of a Hill-Sachs lesion, the time to surgical stabilisation, the presence of impaction fracture of the glenoid, age, the time of the initial dislocation and the presence of a rotator-cuff tear. In our patients there was a wide range of time between the initial trauma or shoulder dislocation and the first clinical symptoms to surgery and no consistency with the development of osteoarthritis.

Our statistical analysis was limited because of the small number of patients. There is a need for controlled studies to compare the clinical long-term results of bone-marrow stimulation techniques, ACI and matrix or scaffold-associated ACI and autologous osteochondral transplantation at the shoulder. We continue to use osteochondral autologous transplantation for the treatment of limited cartilage lesions of the shoulder.

No benefits in any form have been received or will be received from a commercial party related directly or indirectly to the subject of this article.

## References

- Iannotti JP, Warner JJP. Surgical management of shoulder arthritis in the young and active patient. In: Warner JJP, Iannotti JP, Gerber G, eds. *Complex and revision problems in shoulder surgery*. Philadelphia: Lippincott Williams & Wilkins, 1997:289-302.
- Paley KJ, Jobe FW, Pink MM, Kvitne RS, ElAttrache NS. Arthroscopic findings in the overhand throwing athlete: evidence for posterior internal impingement of the rotator cuff. *Arthroscopy* 2000;16:35-40.
- Siebold R, Lichtenberg S, Habermeyer P. Combination of microfracture and periosteal-flap for the treatment of focal full thickness articular cartilage lesions of the shoulder: a prospective study. *Knee Surg Sports Traumatol Arthrosc* 2003;11:183-9.
- Steadman JR, Briggs KK, Rodrigo JJ, et al. Outcomes of microfracture for traumatic chondral defects of the knee: average 11-year follow-up. *Arthroscopy* 2003;19:477-84.
- Steadman JR, Rodkey WG, Rodrigo JJ. Microfracture: surgical technique and rehabilitation to treat chondral defects. *Clin Orthop* 2001;391(Suppl):362-9.
- Brittberg M, Lindahl A, Nilsson A, et al. Treatment of deep cartilage defects in the knee with autologous chondrocyte transplantation. *N Engl J Med* 1994;331:889-95.
- Maus U, Schneider U, Gravius S, et al. Clinical results after three years use of matrix-associated ACT for the treatment of osteochondral defects of the knee. *Z Orthop Unfall* 2008;146:31-7 (in German).
- Steinwachs MR, Guggi T, Kreuz PC. Marrow stimulation techniques. *Injury* 2008;39(Suppl 1):26-31.
- Bentley G, Greer RB 3rd. Homotransplantation of isolated epiphyseal and articular cartilage chondrocytes into joint surfaces of rabbits. *Nature* 1971;230:385-8.
- Bartlett W, Gooding CR, Carrington RW, et al. Autologous chondrocyte implantation at the knee using a bilayer collagen membrane with bone graft: a preliminary report. *J Bone Joint Surg [Br]* 2005;87-B:330-2.
- Bartlett W, Skinner JA, Gooding CR, et al. Autologous chondrocyte implantation versus matrix-induced autologous chondrocyte implantation for osteochondral defects of the knee: a prospective, randomised study. *J Bone Joint Surg [Br]* 2005;87-B:640-5.
- Horas U, Pelinkovic D, Herr G, Aigner T, Schnettler R. Autologous chondrocyte implantation and osteochondral cylinder transplantation in cartilage repair of the knee joint: a prospective, comparative trial. *J Bone Joint Surg [Am]* 2003;85-A:185-92.
- Knutsen G, Engebretsen L, Ludvigsen TC, et al. Autologous chondrocyte implantation compared with microfracture in the knee: a randomized trial. *J Bone Joint Surg [Am]* 2004;86-A:455-64.
- Knutsen G, Drogset JO, Engebretsen L, et al. A randomized trial comparing autologous chondrocyte implantation with microfracture: findings at five years. *J Bone Joint Surg [Am]* 2007;89-A:2105-12.
- Selmi TAS, Verdonk P, Chabot P, et al. Autologous chondrocyte implantation in a novel alginate - agarose hydrogel: outcome at two years. *J Bone Joint Surg [Br]* 2008;90-B:597-604.
- Gerber C, Lambert SM. Allograft reconstruction of segmental defects of the humeral head for the treatment of chronic locked posterior dislocation of the shoulder. *J Bone Joint Surg [Am]* 1996;78-A:376-82.
- Bugbee WD, Convery FR. Osteochondral allograft transplantation. *Clin Sports Med* 1999;18:67-75.
- Sgaglione NA, Miniaci A, Gillogly SD, Carter TR. Update on advanced surgical techniques in the treatment of traumatic focal articular lesions in the knee. *Arthroscopy* 2002;18(Suppl 1):9-32.

19. **Yagishita K, Thomas BJ.** Use of allograft for large Hill-Sachs lesion associated with anterior glenohumeral dislocation: a case report. *Injury* 2002;33:791-4.
20. **Hangody L, Karpati Z.** New possibilities in the management of severe circumscribed cartilage damage in the knee. *Magy Traumatol Ortop Kezseb Plasztikai Seb* 1994;37:237-43 (in Hungarian).
21. **Hangody L, Kish G, Karpati Z, Szerb I, Udvarhelyi I.** Arthroscopic autogenous osteochondral mosaicplasty for the treatment of femoral condylar articular defects: a preliminary report. *Knee Surg Sports Traumatol Arthrosc* 1997;5:262-7.
22. **Laprell H, Petersen W.** Autologous osteochondral transplantation using the diamond bone-cutting system (DBCS): 6-12 years' follow-up of 35 patients with osteochondral defects at the knee joint. *Arch Orthop Trauma Surg* 2001;121:248-53.
23. **Duchow J, Hess T, Kohn D.** Primary stability of press-fit implanted osteochondral grafts: influence of graft size, repeated insertion, and harvesting technique. *Am J Sports Med* 2000;28:24-7.
24. **Iwasaki N, Kato H, Ishikawa J, Saitoh S, Minami A.** Autologous osteochondral mosaicplasty for capitellar osteochondritis dissecans in teenaged patients. *Am J Sports Med* 2006;34:1233-9.
25. **Takahara M, Mura N, Sasaki J, Harada M, Ogino T.** Classification, treatment, and outcome of osteochondritis dissecans of the humeral capitellum: surgical technique. *J Bone Joint Surg [Am]* 2008;90-A(Suppl 2):47-62.
26. **Wechselberger G, Ohlbauer M, Pulzl P, Schoeller T.** Reconstruction of the index metacarpophalangeal joint with an osteochondral metatarsal head graft. *Handchir Mikrochir Plast Chir* 2003;35:263-6 (in German).
27. **Tang P, Imbriglia JE.** Osteochondral resurfacing (OCRPRC) for capitate chondrosis in proximal row carpectomy. *J Hand Surg [Am]* 2007;32:1334-42.
28. **Rittmeister M, Hochmuth K, Kriener S, Richolt J.** Five-year results following autogenous osteochondral transplantation to the femoral head. *Orthopade* 2005;34:320,322-6 (in German).
29. **Weisz MA.** Focal osteochondral necrosis of the femoral head of an adult after Legg-Calve-Perthes disease in childhood. *Z Orthop Ihre Grenzgeb* 2006;144:427-31 (in German).
30. **Magnussen RA, Dunn WR, Carey JL, Spindler KP.** Treatment of focal articular cartilage defects in the knee: a systematic review. *Clin Orthop* 2008;466:952-62.
31. **Bentley G, Biant LC, Carrington RW, et al.** A prospective, randomised comparison of autologous chondrocyte implantation versus mosaicplasty for osteochondral defects in the knee. *J Bone Joint Surg [Br]* 2003;85-B:223-30.
32. **Schafer DB.** Cartilage repair of the talus. *Foot Ankle Clin* 2003;8:739-49.
33. **Gobbi A, Francisco RA, Lubowitz JH, Allegra F, Canata G.** Osteochondral lesions of the talus: randomized controlled trial comparing chondroplasty, microfracture, and osteochondral autograft transplantation. *Arthroscopy* 2006;22:1085-92.
34. **Bobic V.** Autologous osteochondral grafts in the management of articular cartilage lesions. *Orthopade* 1999;28:19-25 (in German).
35. **Hangody L, Fules P.** Autologous osteochondral mosaicplasty for the treatment of full-thickness defects of weight-bearing joints: ten years of experimental and clinical experience. *J Bone Joint Surg [Am]* 2003;85-A(Suppl 2):25-32.
36. **Makino T, Fujioka H, Kurosaka M, et al.** Histologic analysis of the implanted cartilage in an exact-fit osteochondral transplantation model. *Arthroscopy* 2001;17:747-51.
37. **Scheibel M, Bartl C, Magosch P, Lichtenberg S, Habermeyer P.** Osteochondral autologous transplantation for the treatment of full-thickness articular cartilage defects of the shoulder. *J Bone Joint Surg [Br]* 2004;86-B:991-7.
38. **Chapovsky F, Kelly JD 4th.** Osteochondral allograft transplantation for treatment of glenohumeral instability. *Arthroscopy* 2005;21:1007.
39. **Samilson RL, Prieto V.** Dislocation arthropathy of the shoulder. *J Bone Joint Surg [Am]* 1983;65-A:456-60.
40. **Constant CR, Gerber C, Emery RJ, et al.** A review of the Constant score: modifications and guidelines for its use. *J Shoulder Elbow Surg* 2008;17:355-61.
41. **Lysholm J, Gillquist J.** Evaluation of knee ligament surgery results with special emphasis on use of a scoring scale. *Am J Sports Med* 1982;10:150-4.
42. **Hovellius L, Augustini BG, Fredin H, et al.** Primary anterior dislocation of the shoulder in young patients: a ten-year prospective study. *J Bone Joint Surg [Am]* 1996;78-A:1677-84.
43. **Ogawa K, Yoshida A, Ikegami H.** Osteoarthritis in shoulders with traumatic anterior instability: preoperative survey using radiography and computed tomography. *J Shoulder Elbow Surg* 2006;15:23-9.
44. **Marx RG, McCarty EC, Montemurro TD, et al.** Development of arthrosis following dislocation of the shoulder: a case-control study. *J Shoulder Elbow Surg* 2002;11:1-5.
45. **O'Neil RB.** Arthroscopic Bankart repair of anterior detachments of the glenoid labrum: a prospective study. *J Bone Joint Surg [Am]* 1999;81-A:1357-66.
46. **Rosenberg BN, Richmond JC, Levine WN.** Long-term followup of Bankart reconstruction: incidence of late degenerative glenohumeral arthrosis. *Am J Sports Med* 1995;23:538-44.
47. **Konig DP, Rutt J, Tremel O, Kausch T, Hackenbroch MH.** Osteoarthritis following the Putti-Platt operation. *Arch Orthop Trauma Surg* 1996;115:231-2.
48. **van der Zwaag HM, Brand R, Obermann WR, Rozing PM.** Glenohumeral osteoarthritis after Putti-Platt repair. *J Shoulder Elbow Surg* 1999;8:252-8.
49. **Allain J, Goutallier D, Glorion C.** Long-term results of the Latarjet procedure for the treatment of anterior instability of the shoulder. *J Bone Joint Surg [Am]* 1998;80-A:841-52.
50. **Hovellius L.** Anterior dislocation of the shoulder in teen-agers and young adults: five-year prognosis. *J Bone Joint Surg [Am]* 1987;69-A:393-9.
51. **Buscayret F, Edwards TB, Szabo I, et al.** Glenohumeral arthrosis in anterior instability before and after surgical treatment: incidence and contributing factors. *Am J Sports Med* 2004;32:1165-72.
52. **Calandra JJ, Baker CL, Uribe J.** The incidence of Hills-Sachs lesions in initial anterior shoulder dislocations. *Arthroscopy* 1989;5:254-7.