

Chronic locked posterior shoulder dislocation with severe head involvement

Iosif Gavriilidis · Petra Magosch · Sven Lichtenberg ·
Peter Habermeyer · Jörn Kircher

Received: 3 December 2008 / Revised: 16 February 2009 / Accepted: 16 February 2009
© Springer-Verlag 2009

Abstract Arthroplasty is the treatment of choice for severely damaged humeral heads in chronic locked posterior dislocation of the shoulder. We retrospectively reviewed the results of 12 shoulder arthroplasties (11 patients) between 1999 and 2005. Mean follow-up was 37.4 ± 16.8 months. Mean postoperative Constant score (CS) was 59.4 ± 21.6 (normative age and gender-related CS 67.1 ± 24). There was a significant improvement in range of motion for flexion, abduction and external rotation. There was negative correlation (Pearson's coefficient) between the related CS and number of previous operations, pain and duration of symptoms. One patient underwent revision surgery 36 months postoperatively with polyethylene insert exchange. There were two patients with mild and one with severe migration of the humeral head. Shoulder arthroplasty resulted in good midterm results for this patient group with benefits for range of motion, pain and patient satisfaction.

Introduction

Chronic locked posterior dislocation of the shoulder is an uncommon and sometimes missed injury of the shoulder with an incidence of 2–5% of all shoulder dislocations [1, 3]. This specific type of injury usually occurs in patients with significant medical conditions and the treatment is often compromised by a delay in presentation until final diagnosis. The hallmark for the correct diagnosis is a complete radiographic series with a true anteroposterior view, as well as axillary and lateral views combined with a

thorough physical examination. Further diagnostic imaging (CT, MRI) is often necessary to look for other injuries such as rotator cuff tears and the judgment of the amount of involved joint surface. First-time traumatic posterior dislocations include simple dislocations, which are usually accompanied by an anterior osteochondral impression fracture of the humeral head (reversed Hill-Sachs lesion), and the true fracture-dislocations, which are accompanied by more complex fractures of the tuberosities and/or proximal part of the humerus [12].

The different treatment options, such as supervised neglect, closed reduction [14], transfer of the subscapularis tendon [9], transfer of the lesser tuberosity [7], rotational osteotomy of the humerus [10, 18], allograft reconstruction [5], hemiarthroplasty and total shoulder arthroplasty, depend on the duration of the dislocation, the extend of the damage of the articular surface and the whole humeral head, the condition of the glenoid and the general health of the patient [2, 3, 7, 11, 14, 16].

Arthroplasty is used to treat dislocations associated with a large humeral head defect or those associated with deformity or osteoarthritis of the humeral head [2, 7, 14].

The objective of this study was to prove that shoulder arthroplasty is an appropriate treatment option for this type of injury in cases of more than 45% involvement of the articular surface of the humeral head.

Patients and methods

Between May of 1999 and December of 2005 12 arthroplasties (11 patients, 1 bilateral) for chronic locked posterior dislocation were performed by the senior author (P.H.) at our clinic. All patients had severe pain and extensive damage to the humeral head of more than 45% of

I. Gavriilidis · P. Magosch · S. Lichtenberg · P. Habermeyer ·
J. Kircher (✉)
Shoulder and Elbow Surgery, ATOS Clinic,
Heidelberg, Germany
e-mail: j-kircher@web.de

the articular surface according to Hawkins et al. [4] (Fig. 1a,b). Each of the patients retained the preoperative range of motion and had a minimum follow-up of 13 months (mean=37.4±6.8) or follow-up until the time of revision surgery. All patients were scored for the Constant score (CS) and the age and gender-related CS at follow-up.

Ten of the patients were men. The mechanism of injury was a traffic accident in four cases, an epileptic seizure in three cases, electric shock in one case (bilateral injury), skiing injury in one case and an unknown accidental fall in two cases. In ten cases hemiarthroplasty was performed, six were combined with additional surgery such as Latissimus dorsi transfer or rotator cuff reconstruction. In two cases total shoulder arthroplasty (TSA) was necessary because the glenoid was found to be considerably involved at the time of surgery (Table 1).

All the patients underwent a thorough standardised physical and neurological examination before surgery. The follow-up assessment included physical examination, neurological examination, the Constant score and the normative age and gender-related Constant score.

The radiological control included true anteroposterior, axillary and scapulo-lateral (Y) views before and after surgery. The key aspect to confirm the presence or absence of the locked posterior dislocation was the axillary view. We used computed tomography scanning for five patients to assess the degree of damage to the articular surface (Fig. 1a). The radiographs were reviewed thoroughly for possible glenohumeral subluxation, periprosthetic radiolucency, migration of the humeral component and migration or tilt of the glenoid component in case of total shoulder arthroplasty.

Statistical analysis

For statistical analysis, the SPSS software package (version 13.0, SPSS Inc., Chicago, Illinois) was used. Descriptive statistics included the Wilcoxon signed-rank test for range of motion pre- and postoperatively and Pearson's correlation for relation between the relative CS and its subcategories, number of previous surgeries and duration of symptoms.

Surgical technique

Following general anaesthesia the patient was placed in the beach chair position. The upper body was brought to the edge of the operating table to allow full extension of the arm, which is essential for the exposure of the proximal humerus with an additional Mayo table. A typical deltopectoral approach was used in all cases. After identifying the cephalic vein and the conjoined tendon complex, the deltoid muscle was carefully mobilised and protected. In

four of the cases the superior 2 cm of the pectoralis major were released to provide exposure to the inferior aspect of the subscapularis and the anterior circumflex vessels. Then the arm was externally rotated to further expose the boundaries of the subscapularis and the anterior circumflex vessels. The subscapularis tendon was entirely released beginning at the rotator interval over the top of the biceps and proceeding inferiorly below the level of the anterior circumflex vessels, continuing along the humeral neck. The humerus was externally rotated to facilitate the release of the capsule from the humerus to the six o'clock position on the humerus. After releasing the posterior capsule and all the soft tissue a small elevator was inserted through the rotator interval to the posterior part of the glenoid rim and reduction of the dislocation was accomplished with lateral

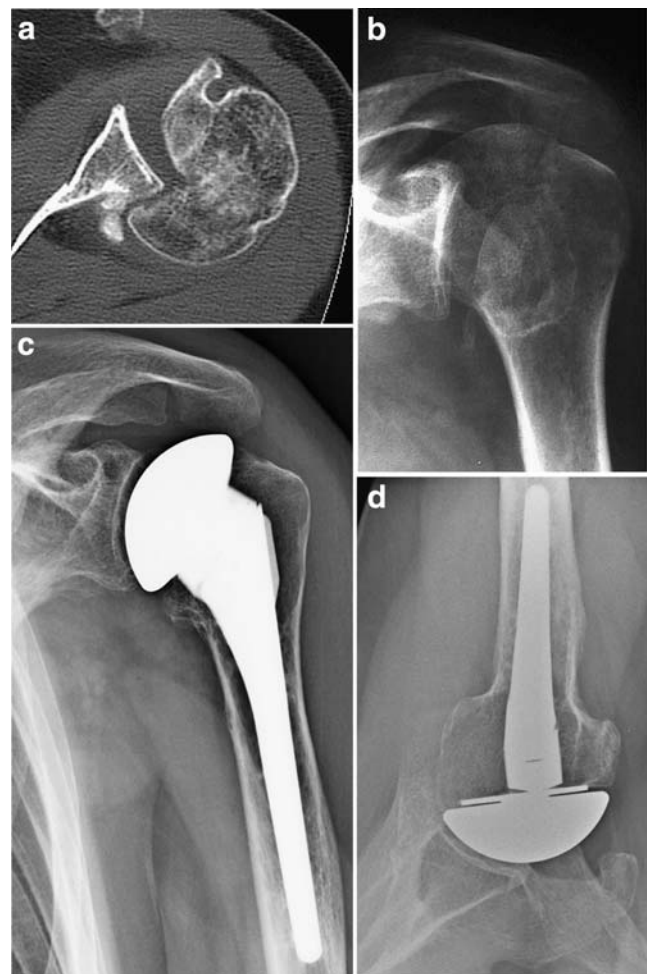


Fig. 1 a Axial CT scan of a left shoulder with locked posterior fracture dislocation with a destruction of the humeral head of more than 50%. b True anteroposterior X-ray (same patient as a). c Postoperative X-ray nine years after hemiarthroplasty at follow-up. There is a centred gleno-humeral joint without massive glenoid erosion. Stress shielding at the humeral metaphysis is noted. d Postoperative X-ray, axillary view. The joint is centred with no marked erosion of the glenoid or radiolucent line at the humeral stem

Table 1 Patient demographics, preclinical findings and details of operation

Patient	Age (y)	Time from trauma to surgery (mo)	Trauma	Involvement of articular surface (%)	Number of previous shoulder surgeries	Shoulder surgery before arthroplasty	Performed index surgery
1	56	4.3	Bicycle accident	45	0	None	Pectoralis major transfer, hemiarthroplasty
2	39	8.8	Fall on ice	45	0	None	Hemiarthroplasty
3	62	5.2	Domestic fall	45	2	Anterior and posterior open stabilisation 5 m before	Hemiarthroplasty
4	59	3.1	Seizure	50	0	None	Total shoulder arthroplasty
5	45	84.0	Skiing accident	45	1	Arthroscopy, ORIF Bankart fracture and SCP transfer 7 y before	Total shoulder arthroplasty
6	64	6.5	Bicycle accident	45	0	None	Hemiarthroplasty
7	45	11.4	High current accident	60	1	Open reduction 11 mo before	Hemiarthroplasty + Latissimus dorsi transfer
8	39	10.6	Motorcycle accident		2	2× ORIF 11 mo before	Hemiarthroplasty
9	44	3.0	Seizure	50	0	None	Hemiarthroplasty + open rotator cuff repair
10	46	32.2	High current accident	60	1	Open reduction 12 mo before	Hemiarthroplasty + Latissimus dorsi transfer
11	51	1.9	Seizure after brain tumour operation	60	0	None	Hemiarthroplasty
12	48	4.1	Car accident	50	1	ORIF	Hemiarthroplasty

ORIF open reduction internal fixation

distraction and external rotation. Unhooking the humeral head from the glenoid rim was more difficult in five cases, and then resection of the humeral head was performed with a special resection guide. The humeral component was inserted in anatomical retroversion of the patient (between 20° and 40°). The stability of the component was checked in 80° of internal rotation and 40° of external rotation. In case of severe damage of the glenoid cavity additional glenoid replacement was performed.

The hemiarthroplasties were uncemented in nine shoulders and cemented in one shoulder using nine Uniers components and one fracture prosthesis (Arthrex, Naples, FL). The two total shoulder arthroplasties were uncemented with a metal-backed glenoid component with a 4 mm polyethylene insert. Postoperatively the shoulders were placed in an abduction pillow in neutral position for three weeks to allow the posterior capsule to heal without tension. A rehabilitation program was started on the second postoperative day with passive range of motion exercises. Limited active range of motion exercises with forward flexion and external rotation was started at six weeks.

Results

The mean age of the patients at the time of index surgery was 49.8±8.6 years. The mean number of previous operations was 0.8±0.9, and the mean duration of symptoms before operation was 14.5±23.3 months.

Constant score

The mean CS postoperatively was 59.5±21.6 points and the mean related CS was 67.1±24.1%. The mean values for the subcategories of CS were 12.8±3.9 points for pain, 14.3±6.1 points for activities of daily living, 26±9 points for range of motion and 9.3±3.6 points for strength.

Range of motion

The mean active flexion increased from 84.2±22.3 preoperative to 125±47 postoperative. Mean active abduction increased from 55.4±21 to 95.8±53.3 and mean external rotation from -6.7±20.2 to 36.7±19.7. The improvement for flexion ($p=0.021$), abduction ($p=0.007$) and external

rotation ($p=0.003$) after index surgery was statistically significant.

Correlations

We observed a negative correlation (Pearson's coefficient) between related CS and the number of previous operations ($r=-0.594$, $p=0.042$) and also between postoperative pain and duration of symptoms ($r=-0.709$, $p=0.010$).

Radiographic evaluation

At the follow-up assessment one shoulder was found to have a dissociation of the polyethylene-inlay from the metal-backed uncemented glenoid component.

We considered upward migration as mild when it was 5–10 mm from the centre line of the joint and severe when it was more than 10 mm. Two shoulders were found to have a mild migration and one shoulder a severe migration of the humeral component. There was no evidence of periprosthetic radiolucency or loosening of any of the humeral or the glenoid components (Fig. 1c, d).

Complications and revisions

One patient needed revision surgery 36 weeks postoperatively with removal of the metal-backed uncemented glenoid component and implantation of a cemented all-polyethylene glenoid component at another hospital. There was no infection, neurological injury, wound-healing problem or glenohumeral subluxation. No recurrence of posterior instability was noted by the patient or at follow-up investigation.

Discussion

According to Cicak chronic locked posterior dislocation of the shoulder is a missed acute posterior dislocation which has been unrecognised for more than three weeks and characteristically there is an impression fracture of the articular surface of the humeral head [4]. The absence of clear radiographic signs in the true AP view without performing an axillary view and cursory clinical examination can lead to a missed diagnosis and delay of proper treatment. The patients in our series had a mean delay until final surgery of more than 14 months, although some of them had had attempts at surgical treatment before, as illustrated in Table 1.

All patients derived benefit from the operation with a significant increase in range of motion. Patients with a short period of time between trauma and index surgery and no

previous shoulder surgery were most likely to have a good Constant score and to have less pain.

Our results (with the majority of cases being hemiarthroplasties) for function are less good than the successful hemiarthroplasties for osteoarthritis (although there is a range of function and pain related to the underlying disease, age of the patient, function before operation and duration of symptoms), but comparable to that of other authors for arthroplasty for the chronically locked posterior dislocations [3, 7, 11, 16]. Better results for pain and function could have been expected with a higher number of total shoulder arthroplasties compared to hemiarthroplasties [8, 15, 17, 20]. However the low average age of the patients in our study demands the use of hemiarthroplasty whenever possible because of the intrinsic risk of wear and loosening, glenoid bone stock erosion and the necessity of revision surgery in the future; although, the risk of a less favourable result is increased for secondary conversion to total shoulder arthroplasty compared to primary TSA [19].

In this study we performed ten hemiarthroplasties and two total shoulder arthroplasties for chronic locked posterior dislocation with severe head involvement. One of the total shoulder arthroplasties presented with a dissociation of the polyethylene inlay from the metal-backed glenoid component 36 months postoperatively. This is a very rare complication and not directly related to the underlying problem in this series.

We observed one severe migration of the humeral component 44 months postoperatively due to a rotator-cuff rupture confirmed by ultrasound. The patient did not undergo revision surgery. He had undergone open reduction 11 months before and needed a Latissimus dorsi-transfer for subscapularis insufficiency at the time of index surgery. Of the eight hemiarthroplasties we had two mild migrations of the humeral components at 15 and 44 months postoperatively. This is a rather common complication after shoulder arthroplasty associated with less favourable functional results and is more frequent after hemiarthroplasty compared to TSA [6].

Robinson separated posterior dislocations to simple dislocations and fracture-dislocations with a concomitant displaced fracture of the humeral head typically at the anatomical neck [12, 13]. The 24 patients in that study underwent surgery within an average of 14 hours after referral with open reduction and internal fixation. At two years after surgery the mean Constant score was 83.5, active flexion was 172°, and active abduction was 169°. Active external rotation was full except for two patients with losses of 10° and 24° respectively. These functional results are all better than those in our series. The results for external rotation seem to be comparable.

Checchia et al. reported considerably worse functional results for conservative treatment in a small series in 1996

[2]. This underlines the necessity for a correct diagnosis and the earliest possible invasive intervention.

The diagnosis must be suspected based on a thorough clinical examination especially when there is a history of significant trauma, electric shocks or epileptic seizure. The critical point in the assessment of this injury is the standard trauma series including true anteroposterior, axillary and scapulo-lateral (Y) radiographs [7]. The axillary lateral view is the most important and it also allows the size of the defect of the humeral head to be estimated. In case of any diagnostic doubt, computed tomography scanning should be performed to facilitate the decision-making process [7].

Shoulder arthroplasty is one of the treatment options, but in the literature there has been little information available regarding the results of this procedure for chronic locked posterior dislocation of the shoulder. Hawkins et al. reported nine hemiarthroplasties and six total shoulder arthroplasties [7]. For the hemiarthroplasties two were performed elsewhere and three required revision to total shoulder arthroplasty for glenoid erosion. For the total shoulder arthroplasties there was one case of recurrent posterior instability. Pritchett and Clark reported three patients with hemiarthroplasty and follow-up of two to three years. There were no cases of recurrent instability and the result was graded as good in each case [11].

Cecchia et al. reported five total shoulder arthroplasties with one good and four unsatisfactory results, including one anterior dislocation. He reported five hemiarthroplasties for acute cases with two good, two fair and one poor result. He also reported eight hemiarthroplasties for chronic cases with a mean follow-up of three years with three excellent, two good, one fair and two poor results with one recurrent posterior instability. Cheng et al. reported seven total shoulder arthroplasties with six good results and one recurrent posterior subluxation in the early postoperative period [2].

Rowe and Zarins reported two hemiarthroplasties with one good and one fair result and one total shoulder arthroplasty, which was performed elsewhere with an excellent result according to a rating scale of 100 units [14].

Cofield et al. had six hemiarthroplasties and six total shoulder arthroplasties with a mean follow-up of nine years in their series. For the hemiarthroplasties there were four good and two fair results with two cases requiring revision because of recurrent posterior dislocation in the early postoperative period. For the total shoulder arthroplasties there were one excellent, two good and three fair results with one case requiring revision because of component loosening [16].

The treatment of this uncommon entity remains challenging and requires a detailed preoperative assessment and surgical planning. New technologies such as CT-scanning with 3D-reconstruction allow better visualisation and

assessment of humeral head involvement and additional fracture lines.

It needs to be emphasised, that there was no recurrence of instability in our series. This is due to a meticulous surgery with a balanced soft tissue release, a cautious reduction manoeuvre, plication of the posterior capsule if necessary and resurfacing and correction of deformity at the glenoid if necessary.

The postoperative rehabilitation program should allow soft tissue healing without tension and prevention of aggressive range of motion exercises which may provoke recurrent dislocation. If the surgeon is aware of these parameters, shoulder arthroplasty turns out to be a very good treatment option for complex injury.

Conclusion

The data of our series supports the concept of arthroplasty for the treatment of chronic locked posterior shoulder dislocation with severe humeral head involvement with very reliable results. It is a technically demanding procedure and should be reserved for high-volume centres. Every attempt should be made to diagnose and treat the injury as soon as possible to prevent severe humeral head damage to maintain the joint without arthroplasty.

References

1. Blasler RB, Burkus JK (1988) Management of posterior fracture-dislocations of the shoulder. *Clin Orthop Relat Res* 232:197–204
2. Cecchia SL, Santos PD, Miyazaki AN (1998) Surgical treatment of acute and chronic posterior fracture-dislocation of the shoulder. *J Shoulder Elbow Surg* 7:53–65
3. Cheng SL, Mackay MB, Richards RR (1997) Treatment of locked posterior fracture-dislocations of the shoulder by total shoulder arthroplasty. *J Shoulder Elbow Surg* 6:11–17
4. Cacak N (2004) Posterior dislocation of the shoulder. *J Bone Joint Surg Br* 86:324–332
5. Gerber C, Lambert SM (1996) Allograft reconstruction of segmental defects of the humeral head for the treatment of chronic locked posterior dislocation of the shoulder. *J Bone Joint Surg Am* 78:376–382
6. Habermeyer P, Magosch P, Lichtenberg S (2007) Recentering the humeral head for glenoid deficiency in total shoulder arthroplasty. *Clin Orthop Relat Res* 457:124–132
7. Hawkins RJ, Neer CS 2nd, Pianta RM, Mendoza FX (1987) Locked posterior dislocation of the shoulder. *J Bone Joint Surg Am* 69:9–18
8. Hettrich CM, Weldon E 3rd, Boorman RS, Parsons IM 4th, Matsen FA 3rd (2004) Preoperative factors associated with improvements in shoulder function after humeral hemiarthroplasty. *J Bone Joint Surg Am* 86:1446–1451
9. McLaughlin HL (1952) Posterior dislocation of the shoulder. *J Bone Joint Surg Am* 24-A-3:584–590
10. Porteous MJ, Miller AJ (1990) Humeral rotation osteotomy for chronic posterior dislocation of the shoulder. *J Bone Joint Surg Br* 72:468–469

11. Pritchett JW, Clark JM (1987) Prosthetic replacement for chronic unreduced dislocations of the shoulder. *Clin Orthop Relat Res* 216:89–93
12. Robinson CM, Aderinto J (2005) Posterior shoulder dislocations and fracture-dislocations. *J Bone Joint Surg Am* 87:639–650
13. Robinson CM, Akhtar A, Mitchell M, Beavis C (2007) Complex posterior fracture-dislocation of the shoulder. Epidemiology, injury patterns, and results of operative treatment. *J Bone Joint Surg Am* 89:1454–1466
14. Rowe CR, Zarins B (1982) Chronic unreduced dislocations of the shoulder. *J Bone Joint Surg Am* 64:494–505
15. Sperling JW, Cofield RH, Rowland CM (2004) Minimum fifteen-year follow-up of Neer hemiarthroplasty and total shoulder arthroplasty in patients aged fifty years or younger. *J Shoulder Elbow Surg* 13:604–613
16. Sperling JW, Pring M, Antuna SA, Cofield RH (2004) Shoulder arthroplasty for locked posterior dislocation of the shoulder. *J Shoulder Elbow Surg* 13:522–527
17. van de Sande MA, Brand R, Rozing PM (2006) Indications, complications, and results of shoulder arthroplasty. *Scand J Rheumatol* 35:426–434
18. Vukov V (1985) Posterior dislocation of the shoulder with a large anteromedial defect of the head of the humerus. A case report. *Int Orthop* 9:37–40
19. Wallace AL, Walsh WR, Sonnabend DH (1999) Dissociation of the glenoid component in cementless total shoulder arthroplasty. *J Shoulder Elbow Surg* 8:81–84
20. Wirth MA, Tapscott RS, Southworth C, Rockwood CA Jr (2006) Treatment of glenohumeral arthritis with a hemiarthroplasty: a minimum five-year follow-up outcome study. *J Bone Joint Surg Am* 88:964–973